

# Ceruminous adenoma

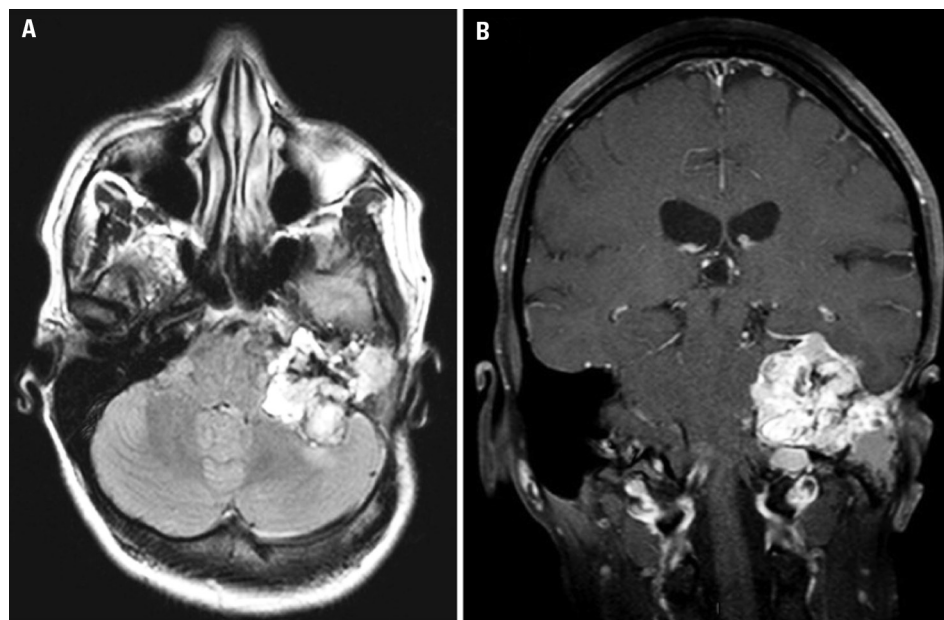
Péricles Maranhão-Filho<sup>1</sup>, Hélio Ferreira Lopes<sup>2</sup>,  
Eliana Teixeira Maranhão<sup>3</sup>, Gabriela Lima<sup>4</sup>

A 27 year-old female patient with an external auditory canal lesion was diagnosed as ceruminous adenoma at the age of 17. She was operated on twice and underwent radiotherapy. The examination shows left prosopagnosia, ipsilateral deafness, and hemiglossoplegia. MRI depicts a heterogeneous lesion in the left temporal bone (Figure). “Ceruminoma” - a term considered by some to be a defunct diagnosis - is a rare, potentially malignant tumour, which presents itself as a yellow mass located to the external auditory canal in 90% of the cases<sup>1,2</sup>. Treat-

ment and prognosis depend on one of the eight currently recognized histomorphologic subtypes (ceruminous and pleomorphic adenoma, cylindrome, adenoid cystic, ceruminous and mucoepidermoide adenocarcinoma, eccrine cylindrome and syringocystiadenoma papilliferum)<sup>2</sup>.

## REFERENCES

1. Neto SC, Duprat A, Freitas EB, et al. Adenoma ceruminoso do ouvido médio (revisão da literatura e apresentação de um caso). *Rev Bras Otorrinolaringol* 1989; 55:179-184.
2. Maheshwari MB, Hejmadi RK, Stores OPR, O'Connell J. Ceruminous gland tumour. *Histopathology* 2002;41: 275-276.



**Figure.** MRI [A] Axial-fluid-attenuated inversion recovery sequence (FLAIR) and [B] Coronal-fat suppressed T1-weighted spin-echo sequence postcontrast that show an irregular enhanced lesion at the petrous portion of left temporal bone with bone destruction, upper tentorium displacement, and extension to cerebellar pontine angle cistern.

## Correspondence

Péricles Maranhão-Filho  
Av. Canal de Marapendi 1680 / 1802  
22631-050 Rio de Janeiro RJ - Brasil  
E-mail: pmaranhaofilho@gmail.com

Received 8 September 2010  
Received in final form 15 October 2010  
Accepted 22 October 2010

## CERUMINOMA

Instituto Nacional de Câncer, Hospital Central I: <sup>1</sup>Neurologist; <sup>2</sup>Neurosurgeon; <sup>3</sup>Physiotherapist, Vestibular Rehabilitation Specialist; <sup>4</sup>Neuroradiologist.